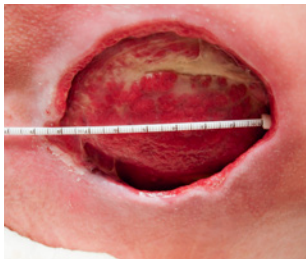
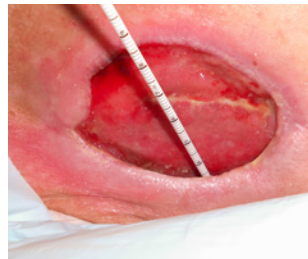

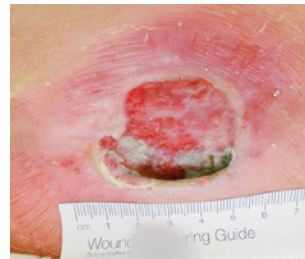# Successful Wound Management in Patient with Challenging Pressure Ulcer



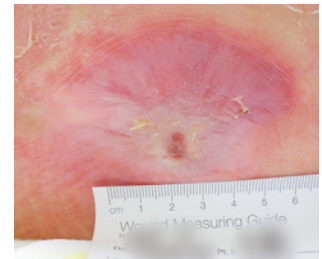
Initial



Week 4



Week 12



Week 23

## Challenge

When this 44-year old male presented with a 4-month old wound that wouldn't heal, the provider knew the patient's health was going to pose a major challenge to the management of the wound. The patient was paraplegic, frail, had contractures and muscle wasting, was tube fed, incontinent and dependent on all care.

## Results

- Fully healed wound
- Dramatic wound area reduction
- Minimal scar contraction
- Reduced dressing changes, down to 1 dressing change every 5-7 days
- Improved patient comfort with less manipulation

## Solution

There was a high likelihood this patient would experience recurring wounds and his wounds would continually be difficult to heal, due his physical limitations and incontinence. Therefore, it was important to find a solution that was both effective and efficient in its application and management.

The provider selected MIRRAGEN® Advanced Wound Matrix, a next-generation intervention for wound management, that is synthetic, absorbable and FDA-cleared. At the initial patient visit, debridement was performed and MIRRAGEN was applied to the wound surface. Additional MIRRAGEN was applied at subsequent patient visits—1 to 2 times per week—until wound closure.

Clinically proven to support rapid tissue healing, MIRRAGEN dramatically reduces healing time for patients, while minimizing treatment costs and improving outcomes.